

Distally Based Axial Pattern Radial Forearm Flap for Reconstruction of Soft Tissue Defects of the Hand

AHMED M. SAMI, M.D. and HAMED M. KADRY, M.D.

The Department of Plastic & Reconstructive Surgery, Faculty of Medicine, Cairo University

ABSTRACT

Soft tissue defects of the hand are commonly encountered problems which are challenging to reconstruct because of the important function of the hand. This is a study of nine patients for whom distally based axial pattern radial forearm flap was used for coverage of hand soft tissue defects. In eight patients, the defects were due to blunt injuries while in one patient, the defect was created after release of post flame burn contracture scar. All the patients were adults. 7 (77.8%) were males and 2 (22.2%) were females. The right hand was affected in 6 (66.7%) patients, with 3 (33.3%) patients had the left hand involved. The flap used was axial pattern fasciocutaneous radial forearm flap in 7 (77.8%) patients and axial pattern adipofascial radial forearm flap in 2 (22.2%) patients. A forearm donor site defect was created in 7 (77.8%) patients which was covered by intermediate thickness split skin graft harvested from the patient's thigh. The donor site was closed with primary sutures in 2 (22.2%) patients. Eight (88.9%) flaps were successful providing stable, padded soft tissue coverage of the hand, near total flap loss occurred in one patient, partial donor site skin graft loss occurred in two patients and cosmetic disfigurement occurred in one patient. In conclusion, distally based axial pattern radial forearm flap is a suitable method for reconstructing tissue loss of the hand and provides optimum hand function and acceptable cosmetic results.

INTRODUCTION

The hand is considered an organ which is enclosing tendon, nerves, vessels, bones and joints, for the hand to function properly, the skin envelope must be strong, elastic and nonadherent to withstand the pressure and friction that are caused by grasping and pinching [1].

The majority of open hand injuries are related to direct trauma inflicted in industrial or agricultural accidents, statistics indicated that the hand is involved in 25-48% of the reported industrial or agricultural accidents [2].

Adequate soft tissue reconstruction is the cornerstone for any successful hand reconstruction. The most meticulously performed reconstructions of the hand are at risk of failure if appropriate soft tissue coverage has not been ensured [3]. The forearm is a suitable candidate for vascularized flaps to cover the hand soft tissue defects [4,5]. Many hand surgeons agree that the islanded radial forearm flap offers several important advantages for covering skin and soft tissue defects of the hand [3].

The radial forearm flap was first described by Yang and Yuzhi in 1978, it was used for lower limb reconstruction [7] and for head and neck reconstruction [8,9].

The use of radial forearm flap was encountered with hand ischemia [10], digital ischemia [11], chronic vascular insufficiency [12] following radial artery division [13] and a skin graft may present a problem at the donor site, particularly if the paratenon of the exposed tendons was not well preserved. Traditionally, cosmesis of the donor site was unsatisfactory [14].

The purpose of this study is to assess the safe use of axial pattern radial forearm flap for covering large hand skin and soft tissue defects.

PATIENTS AND METHODS

This study was conducted on nine patients admitted to Kasr El-Aini teaching hospital, Cairo University from August 2011 to June 2012. Eight patients were suffering from traumatic hand injuries resulting in loss of skin and soft tissue of the hand with exposure of bones and/or tendons, while one patient had a hand skin and soft tissue defect after surgical release of post burn contracture scar.

Patients were subjected to initial clinical examination following the primary then the secondary survey of trauma guidelines to discover life threatening conditions and manage according to priorities. X-rays were done to all patients to assess skeletal injuries. Patients were subjected to coverage of their hand skin and soft tissue defects using distally based axial pattern radial forearm flap.

Patients were fully anesthetized and pneumatic tourniquet was applied to provide bloodless field, the wound was debrided. Fractured small bones were reduced and stabilized where appropriate. Magnification loupes were used in raising all the flaps.

The operation started with planning the length and width of the flap according to defect dimensions. A line was drawn on the skin showing the course of the radial artery from the midpoint of the cubital fossa to distal forearm where the radial artery pulsations are palpable just proximal to the wrist and lateral to the tendon of flexor carpi radialis muscle. An important step was to measure the arc of rotation of the flap so as to determine the length of the vascular pedicle that is needed and which has to be transferred without kinking and tension. In case of fasciocutaneous flap, skin incisions were performed according to flap design. In case of adipofascial flap, the skin incision was S shaped centered on the course of the radial artery, then skin flaps were raised beneath the dermal layer while taking care not to injure the dermal plexus, to leave an adequate amount of subcutaneous fat to be harvested with the flap for adequate padded coverage of the defect. Initially, dissection was started at the ulnar side and once the underlying fascia has been elevated, dissection proceeded to the lateral side. The flexor carpi ulnaris, flexor digitorum superficialis, palmaris longus and flexor carpi radialis muscles were freed from the deep fascia and afterward the fascia was dissected in the septum between the flexor carpi radialis and the brachioradialis. The later dissection has been meticulously performed in the fashion of an envelope or a curtain, as it contains the radial artery and the two accompanying veins, during this step various perforating muscular branches required ligation. Deep retractors were placed over brachioradialis muscle and flexor carpi radialis muscle to provide access to the vessels. Dissection and elevation of the flap including the radial artery and its two vena comitantes was performed from proximal to distal, taking care of safeguarding the superficial radial nerve which courses near to the radial artery in the middle 1/3 of the forearm. Stay

sutures including the deep fascia were applied to the flap edges during elevation to avoid shearing movement. The tourniquet was then released to achieve hemostasis and ascertain good vascularity to the flap using the forceps test, at this stage assessing the circulation of the hand provided by the ulnar artery is done followed by ligating the radial artery and cutting it proximally.

The flap was either tunneled to the defect or the bridge of skin between the base of the flap and the defect was incised and the flap was moved and insetted to the defect with 4-0 vicryl for deep tissues and 4-0 prolene for skin. Vacuum drain was placed underneath the flap. In case of fasciocutaneous flap, skin graft harvested from the patient's thigh was used to cover the forearm donor site skin defect after the bellies of the exposed muscles were approximated. In case of adipofascial flap, primary closure of the donor site using prolene 4/0 was done after insertion of suction drain. Postoperatively, a posterior splint was applied for all patients to avoid wrist motion.

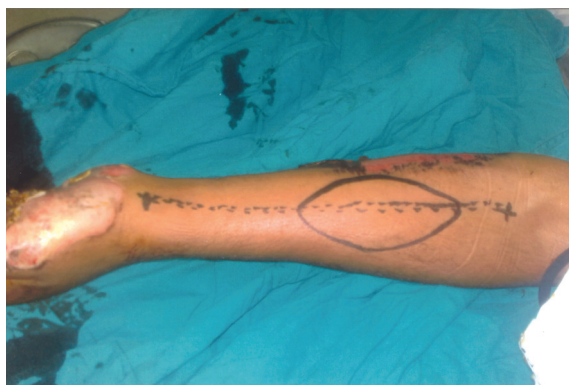RESULTS

Nine patients were included in this study, 7 (77.8%) males and 2 (22.2%) females. The mean age of patients was 27 years (range 18-45). All the patients were adults. Seven defects were due to blunt trauma and one defect was created after post flame burn contracture scar surgical release. The right hand was involved in 6 (66.7%) patients, whereas in 3 (33.3%) patients, the left hand was involved. The patients were suffering from skin and soft tissue loss (average 57.8cm²) over the dorsal aspect, palmar aspect or adductor space of the hand. Five (55.6%) patients had dorsal aspect of hand defects, three (33.3%) patients had palmar aspect of hand defects and one (11.1%) patient had adductor space defect following surgical release of post burn contracture scar. The patients were subjected to distally based axial pattern radial forearm flap for coverage of hand skin and soft tissue defects. The flap size range was from 60-120cm² (average 87.8cm²).

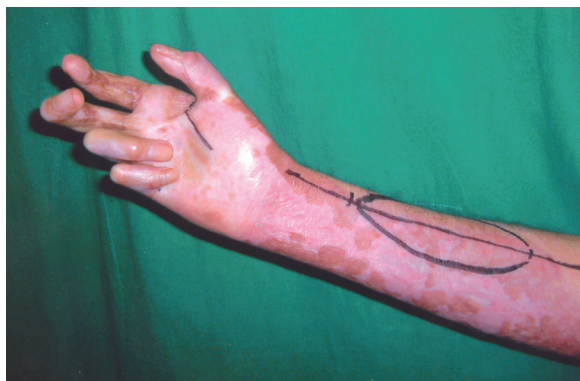Total flap survival was achieved in 8 (88.9%) cases. Reported complications included, near total flap loss in one patient (11.1%), partial donor site graft loss in two from the seven patients who performed fasciocutaneous flap (28.6%) and one patient complained of cosmetic disfigurement (11.1%).

Table (1): Demographic data of patients.

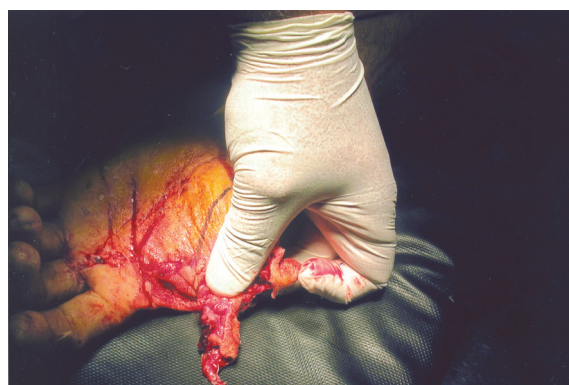
Cases	Age (years)	Sex	Etiology	Defect site	Defect size (cm ²)	Flap size (cm ²)	Flap type	Complications
1	24	M	Flame burn	Adductor space	60	100	Fasciocutaneous	-
2	18	M	Laceration	Palm	70	90	Fasciocutaneous	-
3	32	F	Crushing	Dorsum (radial)	80	120	Fasciocutaneous	Cosmetic disfigurement
4	21	M	Laceration	Dorsum	65	90	Adipofascial	-
5	28	M	Laceration	Palm	50	80	Fasciocutaneous	-
6	45	M	Degloving	Dorsum (ulnar)	70	90	Fasciocutaneous	Partial donor site graft loss
7	22	M	Laceration	Dorsm (radial)	60	100	Adipofascial	Near total flap loss
8	24	F	Laceration	Palm	30	60	Fasciocutaneous	Partial donor site graft loss
9	29	M	Laceration	Dorsum	35	60	Fasciocutaneous	-



(A)

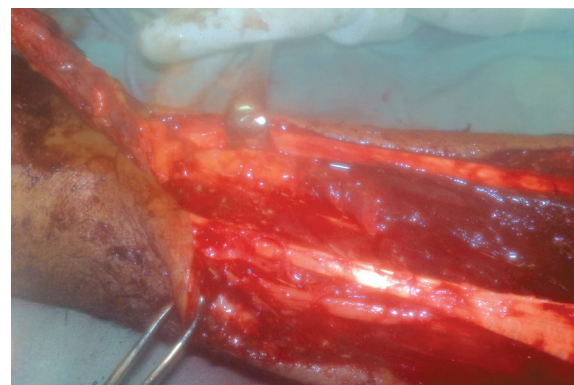


(B)

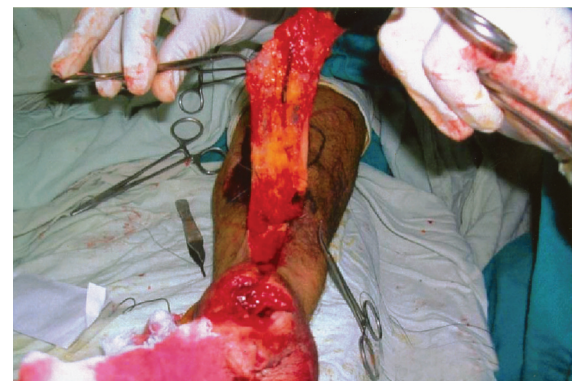


(C)

Fig. (1): Preoperative view of a case of post-traumatic hand skin and soft tissue loss involving the palmar surface of the hand (A), and a case of post burn contracture scar involving the adductor space (B), showing radial forearm flap design. Photo (C) is showing a case of post-traumatic skin and soft tissue loss involving the radial part of the hand.



(A)

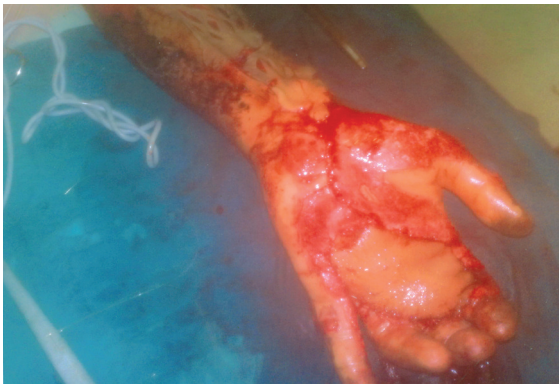


(B)

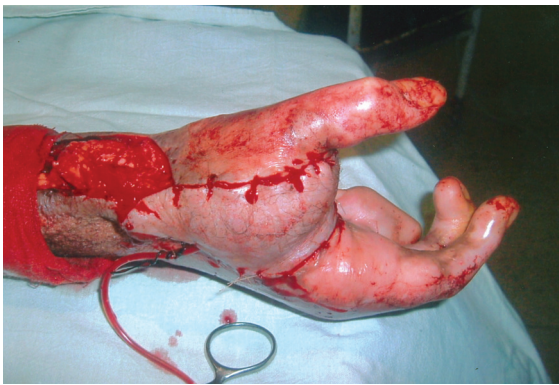
Fig. (2): Dissection and elevation of the flap starts from proximal to distal.

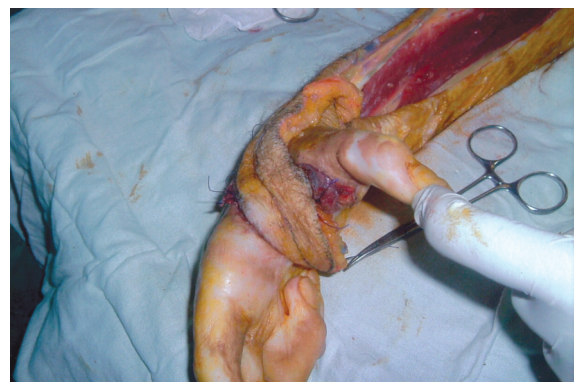

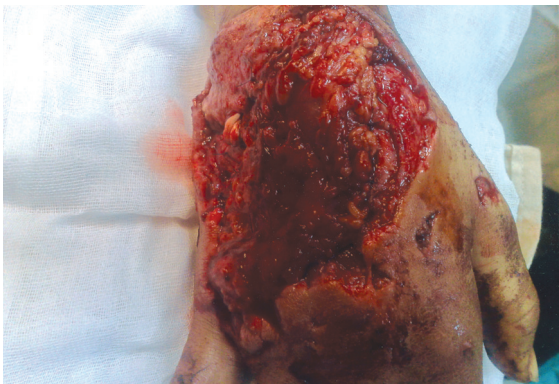
Fig. (3): Fasciocutaneous flap transfer to adductor space skin and soft tissue defect.



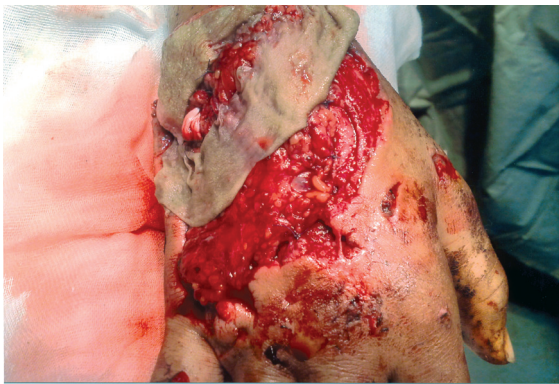(A)



(B)



(C)



(D)

Fig. (4): Intra-operative view showing fasciocutaneous flap inset into palmar surface defect (A) and adductor space defect (B). Photos (C,D) are showing reconstruction of dorsal hand soft tissue defect with adipofascial flap and skin graft.

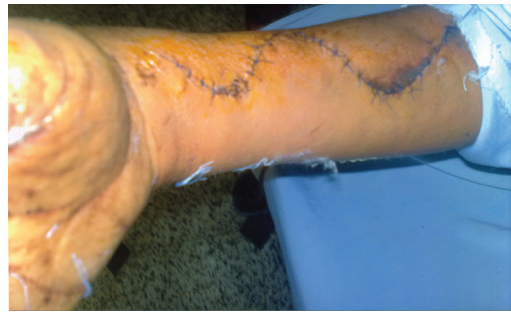
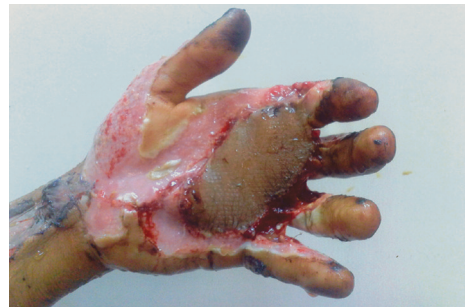
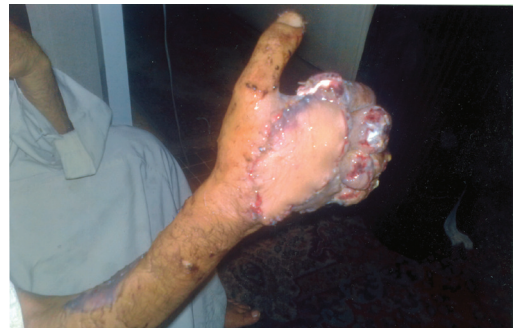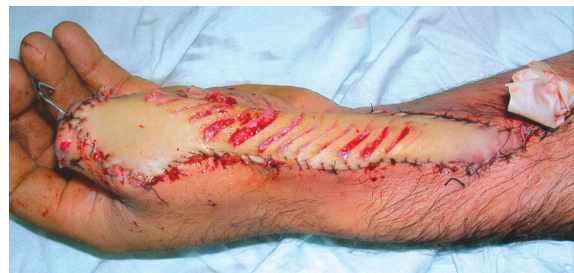Fig. (5): Primary closure of the donor site in a case of adipofascial flap harvest.



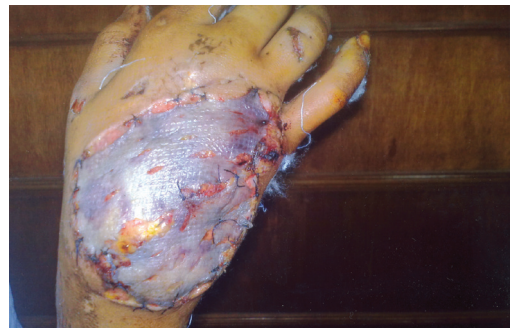(A)



(B)

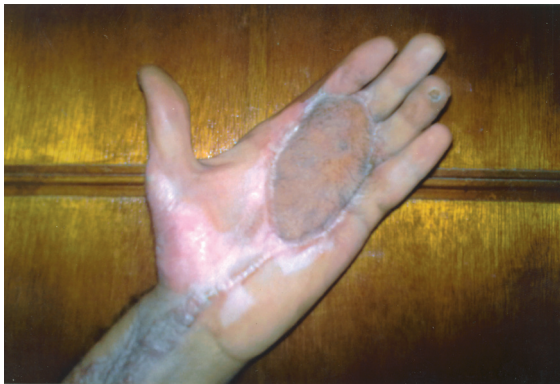

(C)

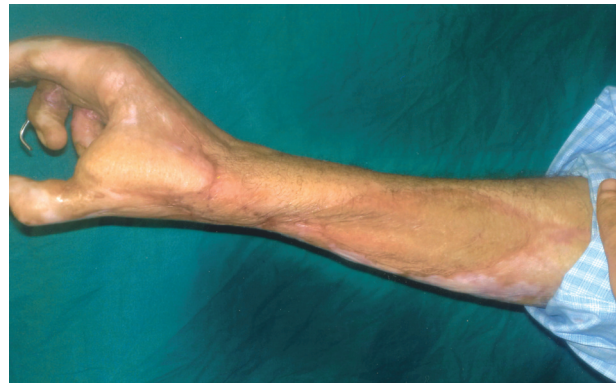


(D)

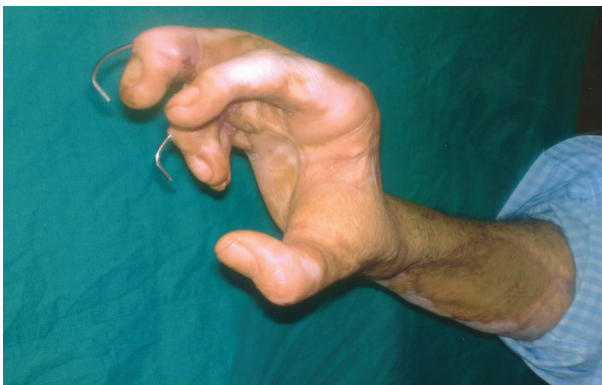Fig. (6): Early postoperative photos of fasciocutaneous flap reconstructing the palmar surface (A) and the dorsal surface (B) of the hand. Photos (C,D) are showing early postoperative photos of adipofascial flap and skin graft reconstructing dorsal hand skin and soft tissue defects.



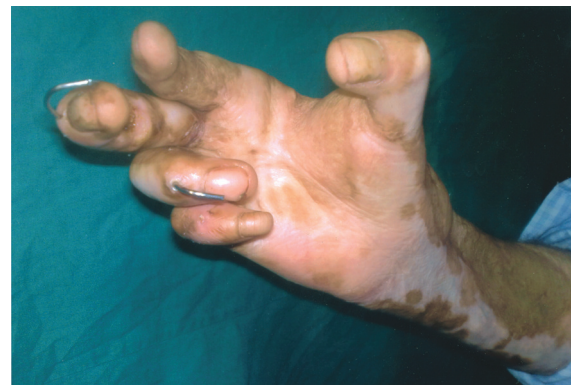(A)



(B)



(C)



(D)

Fig. (7): 3 months following reconstruction with fasciocutaneous flap for palmar surface defect (A) and adductor space defect (B,C,D). Patient in photo (A) was scheduled for flap re-fashioning to reconstruct the web spaces.

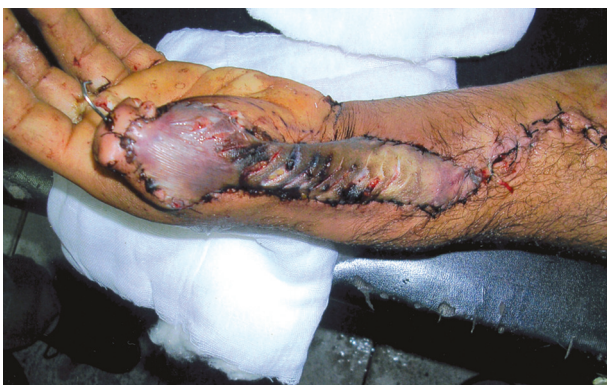

Fig. (8): Near total flap loss in a case of dorsal thumb reconstruction using adipofascial flap.

DISCUSSION

Soucacos et al., 2008, considered radial forearm flap to be one of the basic workhorse flaps for coverage of large hand defects because of its reliability, easy dissection, size flexibility which can include large skin paddles, ability to reach distal areas of the hand and the donor site is confined to the same extremity.

The use of radial forearm flap for hand reconstruction has been considered to be encountered

with ischemic compromise of the hand due to the sacrifice of a major artery of the hand [13]. Acute hand ischemia despite a satisfactory Allen's test can occur after harvesting an axial pattern radial forearm flap [15]. Cosmesis at the donor site of radial forearm flap was considered unsatisfactory [14].

In this study, axial pattern radial forearm flap was used to cover skin and soft tissue defects of the hand. The study revealed that the flap had great versatility in its size and provided a surface area large enough to cover defects greater than 70cm². Moreover, the vascular pedicle was relatively long, and thus usually didn't require the use of a venous graft and the diameter of the lumen of the vessel was large enough to permit adequate blood flow. Dissection and elevation of the flap was straightforward and has been performed with the use of magnification loupes. The flap required no arterial or venous anastomosis, and thus the risk of arterial thrombosis or venous compromise has been minimal.

The sacrifice of radial artery after a satisfactory Allen's test has not been associated with either acute or chronic hand ischemia and the donor site

graft offered acceptable cosmetic results, where the patients' postoperative follow-up was 5 months for 4 patients, 3 months for 1 patient, 2 months for 3 patients and 1 patient didn't attend the postoperative follow-up. Patient satisfaction was achieved in 87.5% of the cases. The patients were scheduled for later reconstruction of their tendon injuries, while one patient has been scheduled for flap re-fashioning to reconstruct the web spaces. Near total flap loss has occurred in one patient, this was probably attributed to the turn over pattern of flap inseting. Wound infection and partial donor site skin graft loss occurred in 2 patients, repeated dressing was done and regrafting after optimization of the graft bed was carried out within 10 days. One patient complained of cosmetic disfigurement.

In conclusion, distally based axial pattern radial forearm flap is reliable, easy to execute, can include large skin paddles, is able to reach distal areas of the hand and gives acceptable functional and cosmetic results when used for coverage of hand skin and soft tissue defects. Vascular compromise may occur when a turnover pattern of flap inseting is performed.

REFERENCES

- 1- Earl Z. Browne Jr. and William C. Pederson: Skin grafts and skin flaps. (book auth.) David P. Green. Green's Operative Hand Surgery. New York: ELSEVIER, 2005.
- 2- Angermann P. and Lohmann M.: Injuries to the hand and wrist: A study of 50,272 injuries. J. Hand Surg., 18B: 642-4, 1993.
- 3- Panayotis N. Soucacos, Aristides B. Zoubas, Anastasios V. Korompilias and Marios D. Vekris: Versatility of the island forearm flap in the management of extensive skin defects of the hand. Inter. J. of the Care of Injured, ELSEVIER, 2008.
- 4- Soucacos P.N., Beris A.E. and Xenakis T.A.: Forearm flap in orthopaedic and hand surgery. Microsurgery, 13: 170-4, 1992.
- 5- Sherif M.M.: First dorsal metacarpal artery flap in hand reconstruction: Anatomical study. J. Hand Surg., 19A: 26-31, 1994.
- 6- Yang G. and Yuzhi G.: Forearm free skin flap transplantation: Natl. Med. J. China, Vol. 61: 139, 1978.
- 7- Hallok G.G., Rice D.C. and Keblish P.A.: Restoration of the foot using the radial forearm flap. Ann. Plast. Surg., Vol. 20: 14-25, 1988.
- 8- Soutar D.S. and McGregor I.A.: The radial forearm flap in intraoral reconstruction: The experience of 60 consecutive cases. Plast. Reconstr. Surg., 78: 1-8, 1986.
- 9- Genden E.M., Wallace D.I., Okay D. and Uraken D.T.: Reconstruction of the hard palate using the radial forearm free flap: Indications and outcomes. Head and Neck, Vol. 26: 808-814, 2004.
- 10- Nuno J. and Menash: An unexpected complication after harvesting of the radial artery for coronary artery bypass grafting. Ann. Thorac. Surg., Vol. 66: 929-931, 1998.
- 11- Heller F., Wei W. and Wei F.C.: Chronic arterial insufficiency of the hand with finger tip necrosis 1 year after harvesting a radial forearm free flap. Plast. Reconstr. Surg., Vol. 114: 728-731, 2004.
- 12- Molski M. and Stanczyk J.: Evaluation of donor site morbidity after radial forearm harvesting (In Polish). Chir. Narzadow Ruchu Ortop. Pol., Vol. 65: 601-609, 2000.
- 13- Wood M.: Atlas of reconstructive microsurgery. Aspen Publishers, Inc., P. 45-46, 1990.
- 14- Geogoulis A., Soucacos P.N., Beris A.E., Papageorgiou M.D., Siamisis G. and Vragalas V.: Application of silicon tissue expanders for the direct or indirect coverage of soft tissue defects in the extremities. Acta. Orthopaedica Scandinavica, 66 (Suppl. 264): 38-40, 1995.
- 15- Jones B. and O'Brien C.: Acute ischemia of the hand resulting from elevation of a radial forearm flap. Br. J. Plast. Surg., Vol. 38: 396, 1985.